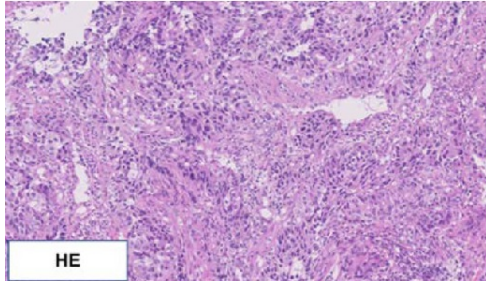
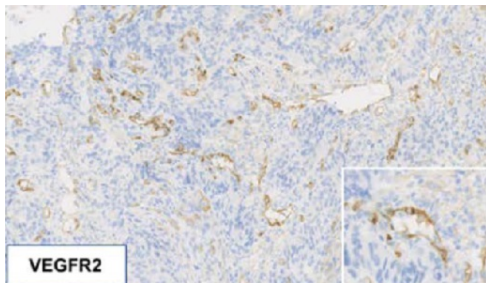


Figure S4.

A)



B)



Vascular endothelial growth factor receptor 2 expression in gastric neuroendocrine carcinoma. 3A: Histopathological findings of gastric NEC on a tumor biopsy showing high-grade malignancy with neuroendocrine features (Hematoxylin and Eosin). 3B: Immunohistochemical staining of a primary gastric NEC showing distinct localization of VEGFR2 in tumor vessels. There is no obvious localization of VEGFR2 in tumor cells in this case (Immunohistochemical stain for VEGFR2).